



ORIGINAL ARTICLE

A clinical audit on the efficacy and safety of uterine artery embolisation for symptomatic adenomyosis: Results in 117 women

Eisen Liang¹ , Bevan Brown² and Maxim Rachinsky³ 

¹Department of Radiology, Sydney Adventist Hospital Clinical School, University of Sydney, Wahroonga, New South Wales, Australia

²Department of Obstetrics and Gynaecology, Sydney Adventist Hospital Clinical School, University of Sydney, Wahroonga, New South Wales, Australia

³Sydney Adventist Hospital Clinical School, University of Sydney, Wahroonga, New South Wales, Australia

Correspondence: Eisen Liang, Sydney Interventional Radiology, SAN Clinic, Sydney Adventist Hospital, 185 Fox Valley Road, Wahroonga, NSW 2076, Australia. Email: eisenliang@gmail.com

Conflicts of Interest: The authors report no conflicts of interest.

Received: 27 April 2017;

Accepted: 3 December 2017

Background: Uterine artery embolisation (UAE) is a possible uterine-sparing treatment option for women with unsuccessful conservative management for adenomyosis-related heavy menstrual bleeding (HMB) and dysmenorrhoea.

Aim: To conduct a clinical audit on the efficacy and safety of UAE for symptomatic adenomyosis.

Materials and Methods: Retrospective review of 309 women who underwent UAE identified 117 women with magnetic resonance imaging features of adenomyosis (junctional zone thickness ≥ 12 mm). Overall success and HMB control were rated by women. Visual analogue scale (VAS) pain score, Uterine Fibroid Symptom and health-related Quality of Life (UFS-QoL) symptoms score and quality of life score were also used to measure outcome.

Results: One hundred and fifteen women (98%) were available for outcome evaluation. The mean follow-up was 22.5 months. Overall clinical success was achieved in 102/115 (89%) women; HMB control was achieved in 91/104 (88%); dysmenorrhea relief was achieved in 94/104 (90%), with VAS reduction of 6.13 ($P < 0.001$), Mean symptoms score was reduced from 58 to 17 at 12 months ($P < 0.001$) and QoL score increased from 42 to 88 at 12 months ($P < 0.001$). Hysterectomy was performed on six (5%) women. There were three (3%) mild groin haematomas and three (3%) mild subacute complications (one possible endometritis, two urinary tract infections; all responded to oral antibiotics). Two women had unintended pregnancies which were complicated.

Conclusions: In this clinical audit UAE was found to be an effective uterine-sparing option for women who had unsuccessful conservative treatments for adenomyosis-related HMB and dysmenorrhoea. There were no major complications. Two women had unintended pregnancies that were complicated.

KEYWORDS

uterine adenomyosis treatment, uterine artery embolisation/embolization

INTRODUCTION

Adenomyosis is a benign disease of the uterus characterised by the presence of ectopic endometrial glands and stroma

within the uterine wall, surrounded by hypertrophic and hyperplastic myometrium. The exact prevalence of adenomyosis is unknown. Adenomyotic tissue can be present in up to 70% of hysterectomy specimens.¹

The symptoms and signs include heavy menstrual bleeding (HMB), dysmenorrhoea, premenstrual and chronic pelvic pain, uterine enlargement and tenderness.²

Adenomyosis may have been a neglected diagnosis in the past. This is due to non-specific symptoms,³ lack of specific tests and lack of specific treatment.⁴ With the advent of transvaginal sonography (TVS) and magnetic resonance imaging (MRI), more accurate diagnosis is possible, potentially enabling more targeted treatment options.⁵ Conservative treatments, such as tranexamic acid,⁶ non-steroidal anti-inflammatory drugs (NSAIDs), combined oral contraceptive pills (OCP)⁷ and levonorgestrel-releasing intrauterine system (LNG-IUS), may be used to control symptoms. Failing these, hysterectomy is often offered as the definitive solution for adenomyosis.

Uterine artery embolisation (UAE) is a non-surgical and potentially uterine-sparing procedure. It has been used to treat symptomatic fibroids since 1995. The safety and effectiveness of UAE to treat fibroids have been established in a Cochrane review.⁸ For women with adenomyosis, many small case series seem to suggest that UAE is a promising option,; however, there are few large case series using this modality.⁹ We aim to report an Australian clinical audit on the efficacy and safety of UAE for symptomatic adenomyosis (Fig. 1).

MATERIALS AND METHODS

For the seven years between March 2008 and March 2015, 309 women underwent UAE in a teaching hospital setting. On

retrospective review of clinical data, 117 women were identified as having MRI features of adenomyosis (with or without fibroids) and were selected for this audit.

MRI diagnosis of adenomyosis was based on high-quality T2-weighted images showing junctional zone thickness of 12 mm or more. This is the most widely accepted diagnostic criterion, with accuracy of 85% and specificity of 96%.¹⁰ Presence of submucosal or myometrial microcysts and adenomyoma add confidence to the diagnosis but were not essential for inclusion into this audit. Presence of fibroids was noted as 'bystander fibroids' if they were deemed unlikely to be contributory to the women's symptoms; or 'symptomatic fibroids' if they were deemed at least partially contributory to the women's symptoms.

Uterine artery embolisation was offered as an option to women who had not benefited from or declined conservative treatments, but wished to conserve the uterus. All potential treatment options including hysterectomy were discussed and offered. The inclusion and exclusion criteria for UAE are listed in Table 1.

Only women with moderate to severe HMB were offered UAE. Severity of HMB was assessed by consensus between the women and the clinician, after discussion of their menstrual issues such as type of pad used, frequency of change during the heavy days, duration of bleeding, whether there is flooding and soiling of cloths and linen. From mid-2009, we also used the Uterine Fibroid Symptom and health-related Quality of Life questionnaire (UFS-QoL),¹¹ to objectively assess the severity of symptoms when discussing treatment options.

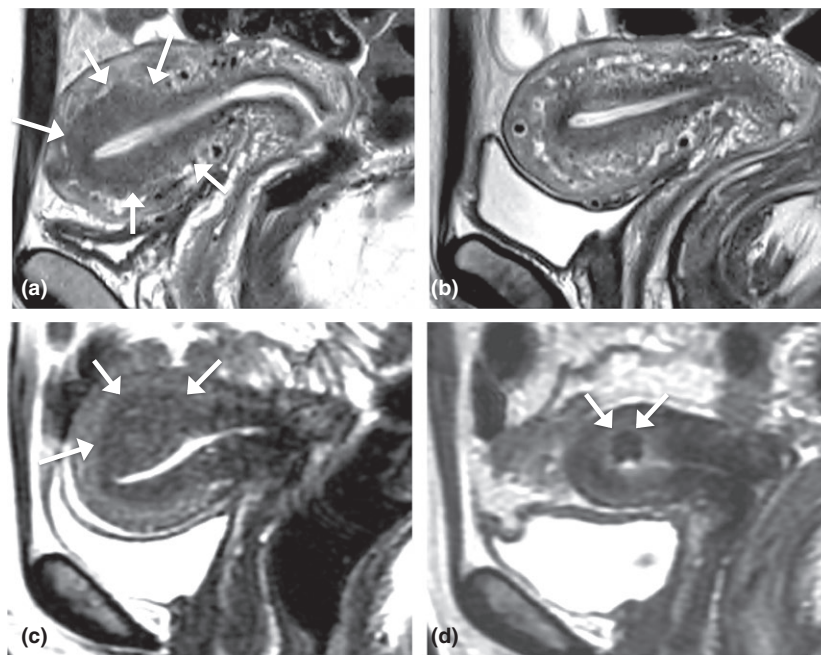


FIGURE 1 Case 1: Twenty eight year old G3P3 with no desire for future pregnancy, presented with severe HMB. NSAIDs were not effective; tranexamic acid has exacerbated dysmenorrhoea; LNG-IUD (Mirena) was not tolerated due to acne and continuous spotting. MRI pre-embolisation (a) showed thickening of junctional zone in the upper body/fundal region. MRI 6 months post-embolisation (b) showed normalisation of junctional zone. Patient reported lessening of menstrual flow, resolution of dysmenorrhoea and improvement of quality of life. Case 2: Fifty two year old G3P3 with severe HMB and dysmenorrhoea. Pre-embolisation MRI (c) demonstrated focal adenomyosis/adenomyoma; Post-embolisation MRI at 6 months (d) showed low signal focus of infarcted adenomyoma.

TABLE 1 Inclusion and exclusion criteria for uterine artery embolisation (UAE)

| Inclusion criteria for UAE: | |
|--|--|
| Significant symptoms of heavy menstrual bleeding, dysmenorrhoea, or bulk symptoms | |
| Demonstrable uterine pathology such as fibroid or adenomyosis | |
| Deemed unsuitable, failed or declined less invasive therapy (medical therapy and levonorgestrel-releasing intrauterine system) | |
| Desire to avoid major surgery | |
| Exclusion criteria for UAE: | |
| Lack of significant symptoms | |
| Absence of relevant uterine pathology on magnetic resonance imaging (MRI) | |
| Presence of endometrial pathology on trans-vaginal ultrasound or MRI such as polyps or endometrial thickening. | |
| Unsuitable uterine mass for embolisation such as avascular/non-viable masses, or submucosal mass with significant protrusion into cavity | |
| Active pelvic infection | |
| Pregnancy | |
| Women seeking a fertility-enhancing procedure | |
| Postmenopausal bleeding or uterine mass enlargement | |
| Contraindication to angiography (contrast allergy, renal impairment) | |

For women who indicated desire for future pregnancy, UAE was not routinely offered, unless all conservative options had been exhausted to control symptoms, and hysterectomy appeared to be the only other option. Women were made explicitly aware that the purpose of UAE is for symptom control but not to enhance fertility.

All UAEs were performed using non-spherical polyvinyl alcohol (PVA) particles (COOK Medical Brisbane, Queensland, Australia). Up to two vials of 300–500 microns PVA were used. If stasis of blood flow was not achieved, 500–700 microns PVA were used. From January 2011 onward, the first vial of PVA used was 200–300 microns. Details of UAE technique have been previously described.¹²

Post-UAE follow ups were at three and six months. Those who had a successful clinical outcome were further followed by phone calls at 12 and 24 months, and again at the closing of the current audit program. Those who were considered not clinically successful at any time were reviewed and offered other treatments.

Women were asked at follow up to rate their response to treatment with three options: (1) very happy; (2) happy; (3) not happy, with women noting 'not happy' designated a clinical failure.

Following UAE, women were asked to rate their menstrual bleeding as 'still heavy', 'back to normal' or 'lighter than normal'. We define 'normal' as menstrual bleeding not causing issues. 'Still heavy' denoted a clinical failure.

For those with dysmenorrhoea, women were asked to rate, at baseline and each follow up, the pain intensity on a Visual

TABLE 2 Clinical profile of audit cohort

| Total number of women audited | 117 |
|-------------------------------------|-----------------------------------|
| Age (mean) | 45 years (median 45, range 30–56) |
| Nulliparous | 8 (7%) |
| Para 1 | 18 (15%) |
| Para 2 | 51 (44%) |
| Para > 2 | 40 (34%) |
| Desiring pregnancy | 7 (6%) |
| Failed LNG-IUS | 23 (20%) |
| Declined LNG-IUS | 3 (2.6%) |
| Heavy menstrual bleed (HMB) | 104 (89%) |
| Severe | 97 (83%) |
| Moderate | 5 (4%) |
| Mild | 2 (2%) |
| No HMB (dysmenorrhoea only) | 13 (11%) |
| Dysmenorrhoea | 105 (90%) |
| Pain score (VAS mean) | 7.5 (median 8, range 1–10) |
| Symptom score (mean)† | 58 (median 56, range 15–100) |
| QoL score (mean)* | 42 (median 41, range 2–90) |
| Baseline MRI findings: | |
| Junctional zone thickness, mm, mean | 20.4 (median 17, range 12–60) |
| Pure adenomyosis | 57 (49%) |
| Adenomyosis and bystander fibroid | 41 (35%) |
| Adenomyosis and symptomatic fibroid | 19 (16%) |

†Baseline UFS-QoL available in 89/117 women (76%).

LNG-IUS, levonorgestrel-releasing intrauterine system; MRI, magnetic resonance imaging; QoL, quality of life; VAS, Visual Analogue Scale.

Analogue Scale (VAS) (or verbal descriptor scale 1–10 if followed over phone). Comparison was made between the final follow up and the baseline.

Clinical outcomes were analysed using the repeated measures Student's *t*-test. Outcomes and PVA particle size analyses were performed using Fisher's exact test.

As this audit conforms to the standards established by the Australian National Health and Medical Research Council (NHMRC) for ethical quality review, ethics committee or Institutional Review Board approval was not required.¹³

RESULTS

The clinical profile of the audit cohort is shown in Table 2: 115 of the 117 cohort (98%) were available for outcome evaluation, two women (1.7%) were lost to follow up. The mean follow up was 22.5 months (median 18 months and range 6–84 months). Clinical success was achieved in 102/115 (89%) women following

TABLE 3 Magnetic resonance imaging changes following uterine artery embolisation

| | Baseline | 6 months | P-value |
|--------------------------------|----------|----------|---------|
| Uterine volume (mL): | | | |
| Mean | 296 | 198 | <0.01 |
| Median | 218 | 171 | |
| Range | 106–1427 | 57–890 | |
| Junctional zone thickness (mm) | | | |
| Mean | 23 | 17 | <0.02 |
| Median | 18 | 14 | |
| Range | 13–61 | 3–48 | |

single UAE; three women had repeat UAE and clinical success was achieved in two women.

Hysterectomy was performed on 6/115 (5%) women. Failure did not appear to be related to PVA sizes (PVA-200 used in 89 women with eight failures; PVA-300 used in 28 women with three failures; $P < 0.0001$).

Overall HMB control was achieved in 91/104 (88%) women following single UAE. Three women had a repeat UAE, with two having successful control of HMB.

For women with dysmenorrhea mean pain score reduced from 7.45 (range 1–10) to 1.32 (range 0–8), with mean reduction of 6.13 ($P < 0.001$).

During the follow-up period, comparison between baseline and final UFS-QoL were available in 48 patients. Symptom score (mean) was reduced from 57 to 17 ($P < 0.0001$) and QoL score (mean) was increased from 45 to 90 ($P < 0.0001$).

MRI changes are shown in Table 3.

There were three (3%) mild procedural-related complications (all mild groin haematomas) and three (3%) mild subacute complications (one possible endometritis, two urinary tract infections, all responded to oral antibiotics). One patient developed thigh paraesthesia following intramuscular injection of antihistamine for a drug allergy.

Amenorrhoea occurred in 15/115 (13%) women at three or six months follow up. The mean age was 50.6 years (median 51, range 46–56). None of these women desired pregnancy before UAE, none were unhappy with the outcome.

Two women became pregnant unintentionally but decided to continue with the pregnancy. The first woman was a 30-year-old G2P2 who underwent UAE for HMB and dysmenorrhoea. She became pregnant three months post-UAE. The pregnancy was complicated with hypertension, gestational diabetes requiring insulin, cervical incompetence, premature rupture of membrane and labour at 33 weeks requiring caesarean section, giving birth to a 2.430 kg (83rd centile) female. At two years of age, the infant was at the 30th centile for both height and weight. The second was a 44-year-old G0P0 with a past history of endometriosis and polycystic ovarian syndrome. She became pregnant seven months post-UAE. Placenta insufficiency and pre-eclampsia were noted at 29 weeks. She delivered a 1.335 kg (<3rd centile) female at 34 weeks. At 16 months

post-delivery, the infant was at the 85th centile for height and 50th centile for weight. Symptoms of severe HMB and dysmenorrhoea were completely resolved at 36 months follow up. Both infants showed no developmental issues or dysmorphic features.

DISCUSSION

Summary of our audit

Overall clinical success was achieved in 90% of women treated with UAE. The cohort showed significant reduction of UFS-QoL symptoms score and improvement of quality of life scores. For dysmenorrhoea, significant mean pain score reduction of 6.13 was achieved. Clinical failure was seen in 10% and hysterectomy was required in 5%. Minor complication rates were low and there were no major complications.

Comparison to other treatments

Medical therapies are often used as first-line treatments for symptomatic control. Tranexamic acid is often used for relief of HMB⁶ and NSAIDs are used for pain. Low-dose continuous combined oral contraceptives pill (OCP) with withdrawal bleeds every 4–6 months may be effective in relieving HMB and dysmenorrhoea.⁷ Gonadotropin-releasing hormone agonists can reduce uterine volume and result in symptomatic relief but their use is limited by hypo-oestrogenic side effects including bone demineralization.¹⁴ However, these treatments have not been tested specifically for adenomyosis.¹

Levonorgestrel intrauterine systems have been shown to be effective in controlling HMB and improving quality of life of women with adenomyosis.² Another study on LNG-IUS for adenomyosis-related dysmenorrhoea showed a satisfaction rate of 56.3% at one year.¹⁵

Endometrial ablation may only be effective for patients with very superficial adenomyosis of less than 2.5 mm.¹⁶ Deep adenomyosis has been associated with an increased failure rate.¹⁷ Unlike fibroids, the boundary with the adjacent myometrium is indistinct and therefore adenomyoma cannot be enucleated.¹⁸

Failing conservative treatments, hysterectomy might have been offered as definitive treatment for HMB and other symptoms, with or without preoperative diagnosis of adenomyosis.

Compared with abdominal hysterectomy, UAE is potentially uterine sparing, less invasive and quicker in recovery.⁸

Comparison to other studies

A previous review summarised UAE in 511 women with adenomyosis from 15 studies (1999–2010), with two series having more than 100 participants (range 2–54). For adenomyosis alone, symptom relief was reported by 83% of women in the short term (9.4 months) and 65% long term (40.6 months). For combined

adenomyosis and leiomyomas, relief was reported in 93% short-term (10.7 months) and 82% in the long term (34.2 months). The hysterectomy rate was 13%, with no deaths or serious adverse events reported.⁹

Three more recent case series published between 2011 and 2015 have 29–40 cases each, mean follow-up of 37–65 months, achieving overall clinical success rate ranging 72.5–76%.^{19–21}

The apparent higher success rate in our audit could be due to a number of reasons. All our UAEs were performed by a single operator with consistent technique. Our follow-up period is shorter than the other groups and delayed failures might yet occur.

In our cohort, the mean symptom score was 58 and mean QoL score was 42. These baseline scores indicate severe symptoms and poor quality of life of the cohort and therefore more likely to allow the procedure to make a difference.

One other plausible reason for our higher observed success rate could be the embolic particles used. We used non-spherical PVA while other groups used tris-acryl gelatin microspheres (TAGM) (Embosphere), polyzene F-coated hydrogel microspheres (Embozene) and acrylamido PVA microspheres (Beadblock).^{19–21}

Strengths and weaknesses

This is a large cohort of women with HMB undergoing UAE, although the issues of a relatively short follow-up time and the subjective nature of assessing both the heaviness of flow and happiness following the procedure may be simple and prone to bias.

Unlike many earlier studies, we have adopted UFS-QoL as our additional clinical tool to objectively assess symptom severity at presentation and follow ups. However, UFS-QoL has not been validated for adenomyosis.

In our cohort, 49% had adenomyosis alone and 51% had co-existing fibroids. In 35% of women the fibroids were considered to be bystanders and 16% of women had fibroids that might be contributory to the symptoms. Therefore, 84% of our cohort had adenomyosis as the presumed underlying cause of symptoms. However, the above assessment is subjective.

Further studies on the effect of UAE on pure adenomyosis might be useful. However, in real-life clinical practice, fibroids and adenomyosis often coexist.

Future research areas

The exact cause and mechanism of HMB and dysmenorrhoea in adenomyosis is still not fully understood. Likewise we are still a long way from understanding exactly how UAE improves adenomyosis-related symptoms. Some have postulated reduction of overall uterine size, endometrial surface and micro-vessel density in the junctional zone to be the contributing factors.²²

Normal myometrium has immense capacity to recruit and open up blood vessels when needs arise, such as pregnancy.

Normal myometrium is also tolerant to ischaemia, as seen in the intense uterine contraction immediately post-partum. However, adenomyotic tissue does not have the capacity to open up vessels when embolised and it is presumably less tolerant to ischaemia compared to normal myometrium. Therefore, necrosis of adenomyoma and reduction of junctional zone thickness after UAE is observed, yet viability of the normal myometrium is demonstrated on contrast-enhanced MRI.

Studies with longer-term follow ups will help to define the durability of this treatment.

Currently there are no randomised control trials comparing UAE and hysterectomy for the treatment of adenomyosis.

There is also lack of data on fertility and pregnancy outcome in women who have been treated with UAE for adenomyosis. The two unintended pregnancies in our audit were complicated. Until further data is available, UAE should not be offered to women who desire future pregnancy.

CONCLUSIONS

Our audit suggests UAE is an effective uterine-sparing treatment option for women who have not benefited from conservative treatments for adenomyosis-related HMB and dysmenorrhoea. There were no major complications. Pregnancy following UAE for adenomyosis is likely to be complicated and cannot be recommended at this time.

REFERENCES

1. Mehaseb MK, Hibaba MA. Adenomyosis uteri: an update. *Obstet Gynecol* 2009; **11**: 41–47.
2. Ozdegirmenci O, Kayikcioglu F, Akgul MA, *et al.* Comparison of levonorgestrel intrauterine system versus hysterectomy on efficacy and quality of life in patients with adenomyosis. *Fertil Steril* 2011; **95**: 497–502.
3. Owolabi TO, Strickler RC. Adenomyosis: a neglected diagnosis. *Obstet Gynecol* 1977; **50**: 424–427.
4. Israel SL, Woutertz TB. Adenomyosis: a neglected diagnosis. *Obstet Gynecol* 1959; **14**: 168–173.
5. Champaneria R, Abedin P, Daniels J *et al.* Ultrasound scan and magnetic resonance imaging for the diagnosis of adenomyosis: systematic review comparing test accuracy. *Acta Obstet Gynecol Scand* 2010; **89**: 1374–84.
6. Azziz R. Adenomyosis: current perspectives. *Obstet Gynecol Clin North Am* 1989; **16**: 221–35.
7. Moghissi KS. Treatment of endometriosis with estrogen-progestin combination and progestogens alone. *Clin Obstet Gynecol* 1988; **31**: 823–8. <https://doi.org/10.1097/00003081-198812000-00008>.
8. Gupta JK, Sinha A, Lumsden MA, Hickey M. Uterine artery embolization for symptomatic uterine fibroids. *Cochrane Database of Systematic Reviews* YR: 2014 NO: 12. [Cited 24 April 2016.] Available from URL: <http://onlinelibrary.wiley.com/doi/10.1002/14651858.CD005073.pub4/abstract>
9. Popovic M, Puchner S, Berzaczy D *et al.* Uterine artery embolization for the treatment of adenomyosis: a review. *J Vasc Interv Radiol* 2011; **22**: 901–909.

10. Novellas S, Chassang M, Delotte J, *et al.* MRI characteristics of the uterine junctional zone: from normal to the diagnosis of adenomyosis. *AJR Am J Roentgenol* 2011; **196**: 1206–1213.
11. Spies JB, Coyne K, Guaou NG, *et al.* The UFS-QOL, a new disease-specific symptom and health-related quality of life questionnaire for leiomyomata. *Obstet Gynecol* 2002; **99**: 290–300.
12. Liang E, Brown B, Kirsop R, *et al.* Efficacy of uterine artery embolisation for treatment of symptomatic fibroids and adenomyosis – an interim report on an Australian experience. *Aust N Z J Obstet Gynaecol* 2012; **52**: 106–112.
13. National Health and Medical Research Council, Australian Government. When does Quality Assurance in Health Care Require Independent Ethical Review? [Cited 22 November 2015.] Available from URL: http://www.nhmrc.gov.au/_files_nhmrc/publications/attachments/e46.pdf
14. Grow DR, Filer RB. Treatment of adenomyosis with long-term GnRH analogues: a case report. *Obstet Gynecol* 1991; **78**: 538–9.
15. Sheng J, Zhang JP, Zhang WY, *et al.* The LNG-IUS study on adenomyosis: a 3-year follow-up study on the efficacy and side effects of the use of levonorgestrel intrauterine system for the treatment of dysmenorrhea associated with adenomyosis. *Contraception* 2009; **79**: 189–93.
16. McCausland VM, McCausland AM. The response of adenomyosis to endometrial ablation/resection. *Hum Reprod Update* 1998; **4**: 350.
17. McCausland AM, McCausland VM. Depth of endometrial penetration in adenomyosis helps determine outcome of rollerball ablation. *Am J Obstet Gynecol* 1996; **174**: 1786–94.
18. Wang PH, Yang TS, Lee WL *et al.* Treatment of infertile women with adenomyosis with a conservative microsurgical technique and a gonadotropin-releasing hormone agonist. *Fertil Steril* 2000; **73**: 1061–2.
19. Froeling V, Scheurig-Muenkler C, Hamm B, Kroencke TJ. Uterine artery embolization to treat uterine adenomyosis with or without uterine leiomyomata: results of symptom control and health-related quality of life 40 months after treatment. *Cardiovasc Intervent Radiol* 2012; **35**: 523–529.
20. Smeets AJ, Nijenhuis RJ, Boekkooi PF, *et al.* Long-term follow-up of uterine artery embolization for symptomatic adenomyosis. *Cardiovasc Intervent Radiol* 2012; **35**: 815–819.
21. Nijenhuis RJ, Smeets AJ, Morpurgo M, *et al.* Uterine artery embolisation for symptomatic adenomyosis with polyzene F-coated hydrogel microspheres: three-year clinical follow-up using UFS-QoL questionnaire. *Cardiovasc Intervent Radiol* 2015; **38**: 65–71.
22. Kitamura Y, Allison S, Jha R, *et al.* MRI of adenomyosis: changes with uterine artery embolization. *Am J Roentgenol* 2006; **186**: 855–864.