

Original Article

## Efficacy of uterine artery embolisation for treatment of symptomatic fibroids and adenomyosis – An interim report on an Australian experience

Eisen LIANG,<sup>1\*</sup> Bevan BROWN,<sup>2</sup> Rodney KIRSOP,<sup>2</sup> Paul STEWART<sup>3</sup> and Andrew STUART<sup>1</sup>

<sup>1</sup>Department of Radiology, <sup>2</sup>Department of Obstetrics and Gynaecology, and <sup>3</sup>Department of Anaesthetics, Sydney Adventist Hospital Clinical School, University of Sydney, New South Wales, Australia

**Background:** Uterine artery embolisation (UAE) has been widely described internationally, however there is a paucity of data reported from Australia.

**Aim:** To conduct a local audit on the efficacy and safety of UAE treating symptomatic fibroids and adenomyosis.

**Methods:** Clinical data of 76 consecutive UAEs were reviewed. Degree of fibroid-related symptoms before embolisation and at follow-up visits were compared. Procedural and subsequent complications were recorded. Uterine and fibroid volumes were measured on MRI at baseline and six months post-UAE.

**Results:** Seventy-six UAEs were performed in 75 women. Fifty-nine women had follow-up duration of more than six months, and one woman was lost to follow-up. Clinical success was 93% overall ( $n = 59$ ) and 96% for menorrhagia ( $n = 49$ ). For dysmenorrhoea ( $n = 36$ ), 89% of women had at least some improvement, 75% had significant improvement and 56% had resolution of pain. For urinary symptoms ( $n = 32$ ), 97% of women had at least some improvement and 50% had resolution of all urinary symptoms. Adenomyosis was found in 17 (29%) women treated. The primary success rate was 96%, and secondary success rate (after repeat UAE) was 100%. MRI showed 50% uterine volume reduction and 60% dominant fibroid volume reduction. There were no significant procedural-related acute complications. There were three possible cases of endometritis, two managed conservatively and one required hysterectomy.

**Conclusions:** This audit, based on local Australian experience, has confirmed that UAE is a safe and highly effective treatment for women with symptomatic fibroids and/or adenomyosis.

**Key words:** adenomyosis, uterine artery embolisation, uterine fibroid.

### Introduction

Uterine artery embolisation (UAE), also known as uterine fibroid embolisation (UFE), is a minimally invasive angiographic procedure. UAE has been used to control post-partum haemorrhage and to reduce intraoperative haemorrhage during myomectomy.<sup>1,2</sup> UAE as a non-surgical treatment for symptomatic fibroids was first described in 1995.<sup>2</sup> The procedure quickly gained popularity. Worldwide, it was estimated that more than

10 000 UAEs had been performed by year 2000,<sup>3</sup> and 100 000 had been performed by 2008.<sup>4</sup>

The Medical Services Advisory Committee (MSAC), of the Australian Government Department of Health and Aging, investigated the safety, efficacy and cost-effectiveness of UAE<sup>3</sup> and recommended that UAE be funded by Medicare in 2006. Since then, there have been two more randomised control trials published, comparing UAE with hysterectomy.<sup>5,6</sup> Based on the results of these trials and prior published results, The American College of Obstetricians and Gynecologists issued a Practice Bulletin and The Royal Australian and New Zealand College of Obstetricians and Gynaecologists issued a College Statement, recognising UAE as a treatment option for symptomatic fibroids.<sup>4,7</sup>

Despite the large volume of literature published on UAE, there are no local Australian data available. A local audit has been called for, to define the risks and benefits of this procedure for Australian women.<sup>8</sup> We responded

\*Correspondence: Dr Eisen Liang, SAN Radiology, Sydney Adventist Hospital, Wahroonga, NSW 2076, Australia. Email: eisenliang@gmail.com

The authors confirm that there is no commercial or other conflict of interest identified.

Received 2 April 2011; accepted 15 November 2011.

by conducting a local audit to confirm the efficacy and safety of this treatment in Australian women.

## Materials and Methods

This is a clinical audit based on review of clinical records specifically designed for UAE women. The clinical data were prospectively collected in a standardised format.

As this review conforms to the standards established by the NHMRC for ethical quality review, ethics approval was not sought.<sup>9</sup>

Seventy-six consecutive UAEs in 75 women were performed from June 2007 to August 2010. Seventy women were treated in a large private teaching hospital in Sydney, and five women were treated in a public hospital on the Central Coast of New South Wales. All women were managed under a multidisciplinary setting. The women were given a brief patient information pamphlet<sup>10</sup> and detailed patient information sheets<sup>11</sup> prior to a formal consultation with the interventional radiologist (IR) at the IR Clinic. Eighty-eight per cent of women were referred by gynaecologists and 12% by general practitioners (GP). When a woman was referred by a GP, a gynaecologist was involved in the treatment plan, in-hospital care and follow-ups. An anaesthetist was engaged in the management of post-procedure pain.

All UAEs were performed under conscious sedation and local anaesthesia. Access was through a 5-Fr sheath in the right common femoral artery. A pigtail catheter aortogram was performed to check for significant ovarian artery supply to the uterus. The left internal iliac artery was then cannulated with a 5-Fr C1 catheter (COOK Medical Australia). Digital subtraction angiography (DSA) runs were avoided where possible to minimise radiation dose. The uterine artery was selectively cannulated with a 2.7-Fr microcatheter (Progreat, Terumo, Japan). The target destination was the distal horizontal segment of the uterine artery, beyond the cervicovaginal branch. Embolisation was performed using polyvinyl alcohol (PVA) particles (COOK Medical Australia). The end point was stasis of contrast remaining in the uterine artery after five heart beats. Up to two vials of 300–500 µm PVA were used, and then up to two vials of 500–700 µm PVA were used. If stasis was still not reached, 700–900 µm PVA was used. Forty milligrams of gentamicin was mixed and injected with the first 20 mL of PVA suspension. The above procedure was then repeated on the right side. The ipsilateral right internal iliac artery was cannulated with the 5-Fr C1 catheter using the Waltman loop technique.<sup>12</sup>

Patient-controlled analgesia, regular paracetamol and non-steroidal anti-inflammatory drugs (NSAIDs) were given for at least the first 24 h. In-hospital care was jointly provided by the gynaecologist, IR and anaesthetist.

Following discharge, the women were initially seen by the IR at days 8–10 to ensure satisfactory recovery. Subsequent follow-ups were shared between IR and gynaecologists. Any adverse events were jointly and promptly managed by IR and gynaecologists.

All women were followed by their gynaecologists for ongoing gynaecological care. Findings at follow-up were communicated by correspondence between the gynaecologists and IR.

Scheduled clinical follow-ups by the IR were performed at 3, 6, 12 and 24 months to systematically document clinical outcomes. At each visit, the degree of menorrhagia and bulk-related symptoms were systematically graded as nil, mild, moderate or severe. For dysmenorrhoea, the visual analogue scale (VAS) was used to grade pain severity: severe (VAS 7–10), moderate (VAS 4–6) and mild (VAS 1–3). Improvements in these symptoms were graded as: complete resolution, significant improvement (from severe to mild), some improvement (severe to moderate, or moderate to mild) or no improvement. Patient satisfaction at these follow-ups was rated as: Very happy, Happy, or Not happy.

Baseline and six-month MRIs were used to document uterine volume reduction and dominant fibroid reduction. Volume was calculated using the formula for a prolate ellipse (length × depth × width × 0.52).

## Results

Seventy-six UAE procedures were performed on 75 women (one woman had a repeat UAE). There were 62 Caucasians, 12 North Asians and one South Asian. The age of the women ranged from 32 to 57 years (mean 47). Eighty-nine per cent did not desire future pregnancy, 6% were not sure and 5% desired future pregnancy.

Up to March 2010, 59 of 60 women (98%) have had a six-month or more follow-up. One was lost to follow-up at six months. Forty-six women (77%) had 12-month follow-up and 22 women (37%) had 24-month follow-up. The overall clinical success rate at six months (defined as happy or very happy with the procedure outcome) is 93% (55 of 59 women). This result appears to be sustained at 12 and 24 months. For those who were happy at six months, none became unhappy at the 12- and 24-month follow-up.

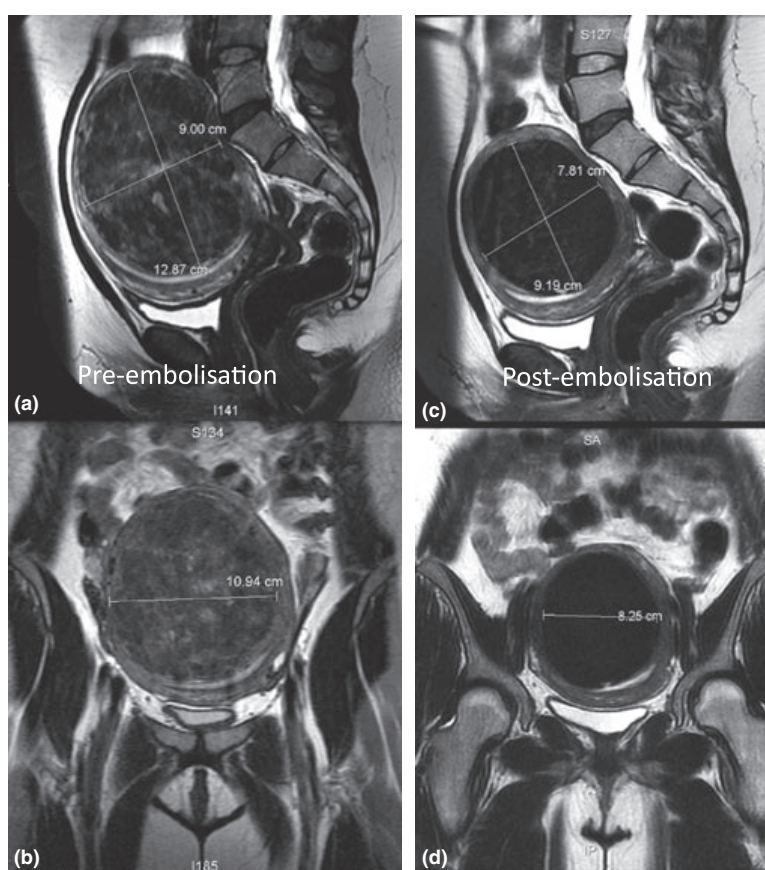
Clinical failure (defined as not happy with the procedure outcome) at six months occurred in four women (7%) (Table 1). This has resulted in two hysterectomies and one repeat embolisation. No additional failures occurred at 12 and 24 months.

There were 49 women with menorrhagia (46 severe, three moderate), 43 had resolution and four had significant improvement. Clinical success (defined as resolution or significant improvement) for menorrhagia was 96%, and this appears durable in that women who were happy at six months remained happy at 12 and 24 months.

The uterine volume reduction was around 50% at six months (mean 50%, range 4–89%). Uterus size treated ranged from 77 to 1767 mL. Reduction in volume of the dominant fibroid was around 60% at six months (mean 59%, range 26–100%). Dominant fibroid size ranged from 91 to 897 mL (Figs 1,2).

**Table 1** Unhappy patients at six months: 4/59 (7%)

Patient and outcome	Details
Patient 1: Elective hysterectomy	2-year menopause, significant urinary symptoms, distension and pelvic pain, patient strongly request UAE. Hysterectomy at 6 months because of persistent pelvic pain. Pathology: Inflamed appendix epiploica
Patient 2: Semi-elective hysterectomy	4 months post-UFE increasing pelvic pain and vaginal bleeding, hot and cold, night sweats, tender uterus. WCC normal. Pathology: Endometritis, focal necrosis and inflammation
Patient 3: Repeat UFE	High-grade glioblastoma multiforme in remission, severe menorrhagia because of diffuse adenomyosis, no fibroid. Some improvement at 3-, 6- and 12-month follow-up. Repeat UFE at 15 months was successful, menses lighter than normal, happy with outcome
Patient 4: Stress incontinence, awaiting pelvic floor surgery	Still the same at 6 months, despite 40% reduction in uterine volume

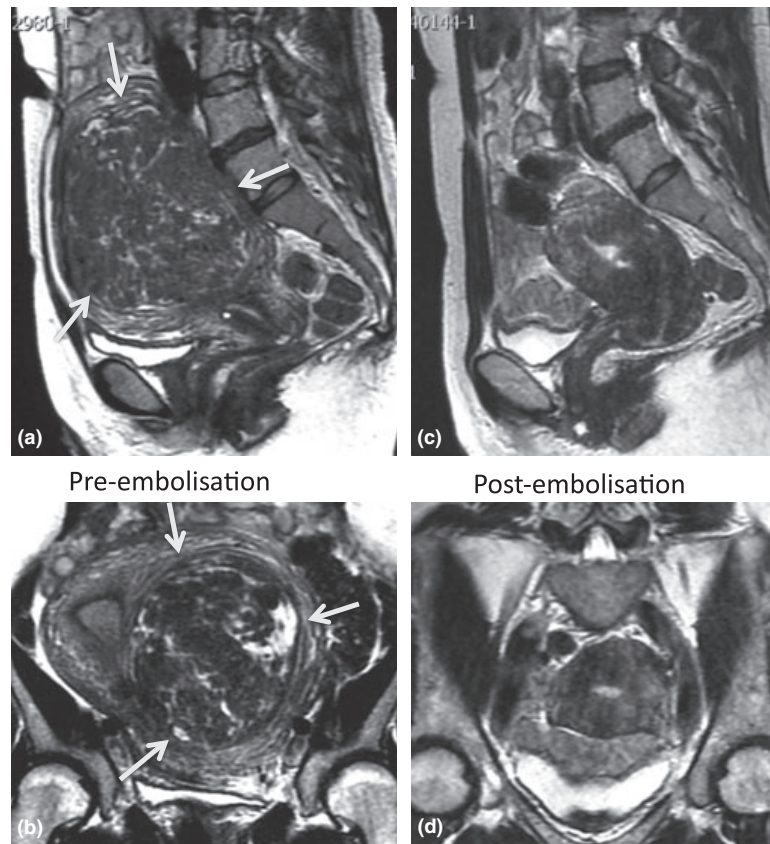


**Figure 1** Typical MRI appearance of a fibroid pre- and post-UFE. On the sagittal (a) and coronal (b) T2-weighted pre-UFE MRI images, the fibroid was measured. Note reduction in size and signal on the corresponding six-month post-UFE MRI images (c, d). The fibroid volume reduced 53%, from 658 to 308 mL.

There were 32 women with urinary symptoms (11 severe and 21 moderate). Nine women had resolution (28%), seven had significant improvement (22%) and 15 had some improvement (47%). Only one woman did not have her urinary symptoms improved after UAE (see

Woman 4, Table 2). Therefore, 50% women had resolution or significant improvement of symptoms, and 47% had some improvement.

There were 36 women with dysmenorrhoea, including 12 with severe pain (VAS 7–10) and 10 with moderate



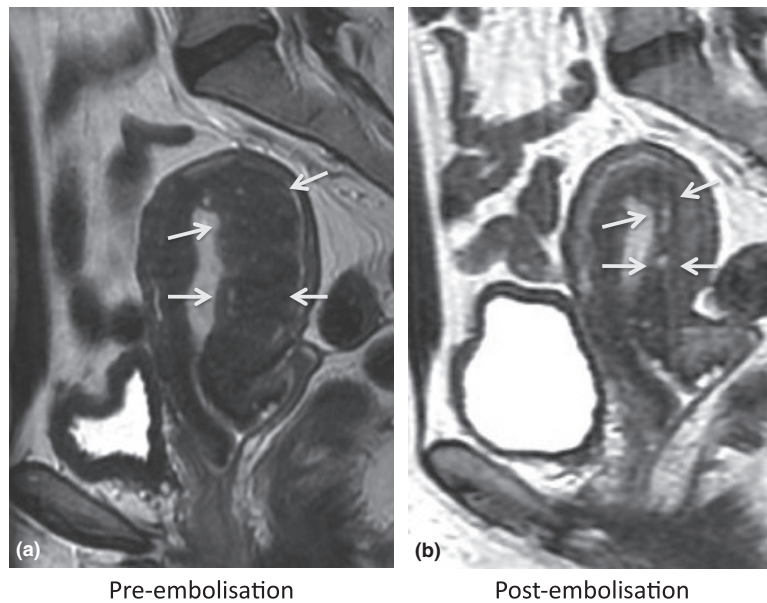
**Figure 2** A case of disappearing large fibroid. 48 yr G0P0 presented with severe menorrhagia and anaemia (Hb 6.3 g/dL), urinary and bulk symptoms. There was a 500-mL fibroid (arrows) on the pre-UFE MRI (a, b) and disappearance of this large fibroid on the six-month post-UFE MRI (c, d). There was also significant reduction in overall uterine volume reduction from 1300 to 129 mL. At six-month follow-up, she had complete resolution of menorrhagia and bulk-related symptoms. This was sustained at 18-month follow-up. The woman had a three-day admission to another institution at two months post-UFE, for pain, fever and vaginal discharge. She was managed conservatively with IV antibiotics and analgesia, with presumed diagnosis of endometritis. She denies passage of any noticeable fibroid masses.

**Table 2** Subacute non-procedural-related complications/adverse effects

Patient diagnosis	Details
Patient 1: ? Endometritis	Readmission on day 5, conservative treatment with antibiotics, very happy with clinical outcome at 6 months
Patient 2: ? Endometritis	Readmission at 2 months, conservative treatment with antibiotics; disappearance of the 500-mL fibroid at 6 month, very happy with clinical outcome at 12 months
Patient 3: ? Endometritis	See Patient 2 Table 2
Patient 4: Pain	Represented at 2 months, passing clots, no increase in white cell count, treated with oral analgesic; dominant fibroid reduced from 880 to 394 mL. Very happy at 24 months
Patient 5: Calf DVT	Despite TED stocking and subcutaneous heparin prophylaxis, developed DVT of calf vein 2 weeks post-UAE. Did not require anticoagulation therapy. Very happy with UAE outcome at 12 months

pain (VAS 4–6). All women with moderate-to-severe pain (22) showed improvement (ten resolution, seven significant improvement and five some improvement).

Adenomyosis was found in 17 women (17/59, ie 29%): six had pure adenomyosis and 11 had coexistent fibroid disease. Of these 17, 15 women had severe menorrhagia



**Figure 3** A case of adenomyosis. 49 yr G2P2 with severe menorrhagia and dysmenorrhoea was reported to have a 2.7-cm submucosal fibroid based on ultrasound findings. Pre-UFE MRI (a) showed no fibroid but marked thickening of the posterior junctional zone (arrows) indicating adenomyosis. Reduction in junctional zone thickening (arrows) was noted on the six-month post-UFE MRI (b). Her menorrhagia and dysmenorrhoea have resolved at six-month and 18-month follow-up.

and seven had severe dysmenorrhoea. All women were happy or very happy with the clinical outcome (94% success rate). One woman required repeat UAE at 15 months and was happy with the outcome afterwards. Therefore, the primary success rate was 94%, and secondary success rate was 100% (Table 3).

Technical failure occurred in one of 76 UAE procedures. A right uterine artery could not be cannulated due to persistent spasm. However, clinical success was achieved despite unilateral embolisation. The woman was happy with the clinical outcome at 6- and 12-month follow-up.

There were no procedural-related acute complications such as groin pseudoaneurysm, blood transfusion, arterial perforations, arterial dissection and non-target embolisation. There were three suspected cases of endometritis, one readmission for pain and one case of deep venous thrombosis (DVT) of the calf (Table 2).

Amenorrhoea developed in 6 of 59 women (10%). All six women were aged over 50 (Range 51–57, Median 52.5). None of the six women desired future pregnancy prior to UAE. All were very happy or happy with the UAE outcome.

The results of the audit were summarised in Table 3.

## Discussion

The clinical records for UAE women were specially designed and structured. The standardised format allows prospective data collection and subsequent comparison of

**Table 3** Clinical outcome summary

Overall ( $n = 59$ )
93% success (73% very happy, 20% happy)
Menorrhagia ( $n = 49$ )
96% success (resolution or significant improvement)
Dysmenorrhoea ( $n = 36$ )
89% has at least some improvement
75% has at least significant improvement
56% complete resolution
Urinary symptoms ( $n = 32$ )
50% significant improvement or resolution of symptoms
97% at least some improvement
Adenomyosis ( $n = 17$ )
96% primary success rate
100% secondary success rate
50% uterine volume reduction at 6 months
60% dominant fibroid volume reduction at 6 months
0% Procedural complications
3 Possible endometritis (5%)
2 Hysterectomies (3%)

fibroid-related symptoms between baseline and subsequent follow-ups.

Of the 76 women, only one was lost to follow-up. The high retention rate of this audit was the result of designated personnel actively managing the follow-up schedule by sending out reminder letters and phone calls if women were overdue for follow-up.

Our overall success rate at six months was 93%. Women who were very happy or happy with the

outcome remained so at subsequent 12- and 24-month follow-ups, suggesting the durability of the result in this cohort. Our success rate for menorrhagia was 96%. The improvement in urinary symptoms was also rewarding, with 50% of women reporting significant improvement or complete resolution, and 97% reporting at least some improvement. For dysmenorrhoea, 89% women have at least some improvement, 75% significant improvement and 56% complete resolution of symptoms.

Our clinical outcome regarding menorrhagia, bulk-related symptoms and dysmenorrhoea appears to be superior to that reported in the literature.<sup>3,5,6,13,14,15</sup> We attribute this to a multidisciplinary approach, careful patient selection, single operator with relatively high case volume, and consistent embolisation technique. We would like to emphasise the importance of the multidisciplinary team management. All women had thorough discussion with gynaecologists and IR regarding the options available to manage their symptoms. UAE was performed when all three parties agreed that UAE was the best option available. The women were under the joint care of the referring gynaecologist, IR and anaesthetist while in hospital. Women were followed by the gynaecologists for ongoing gynaecological care. All adverse events were jointly managed by gynaecologists and IR. Scheduled 3-, 6-, 12- and 24-month follow-ups with the IR using standardised clinical records enabled us to systematically document treatment outcomes.

We acknowledge the weakness of the outcome measure of this audit. We recognise that consensus assessment of the outcome by the woman and treating doctor is subjective. We have started using quality of life questionnaires to measure treatment outcome.<sup>16</sup> We also acknowledge that the follow-up of this audit report is short. We intend to report 24-month follow-up results in the future.

Presence of adenomyosis was common in our cohort. Our result echoed previous reports that UAE should be considered as a primary treatment method for symptomatic adenomyosis.<sup>17</sup>

We had a very low technical failure rate of 1.3%. This compares favourably with 2% in REST trial<sup>6</sup> and 5.3% in Emmy trial.<sup>5</sup> Both trials involved large number of operators and hospitals (106 UAE in 27 hospitals in the REST trial, 88 UAE in 34 hospitals in EMMY trial). The operator experience is likely to be diluted in these trial centres. Our routine use of microcatheters and topical prophylactic glycerol trinitrate patch to prevent vasospasm may contribute to the higher technical success rate.

We did not have any significant procedural-related acute complications. This is in keeping with the literature, confirming that UAE is a safe minimally invasive procedure.<sup>3,5</sup>

Amenorrhoea developed in 10% of our women, all aged over 50 years (mean 53). This is consistent with the MSAC assessment of the available literature that UAE does not appear to affect ovarian function in younger

women, and permanent amenorrhoea tends to occur in older women close to natural menopause.<sup>3</sup> All these women were not unhappy with the outcome.

Pain control post-UAE is an important facet of UAE. We have not addressed this issue in this report. This is because we changed our pain management protocol during the study period; the result of this change is yet to be investigated.

Through our clinical practice, we noticed that many of our women were initially offered hysterectomy without mention of the option of UAE, and quite often, the woman herself, who had conducted her own research on the Internet, requested the referral to IR. Despite the publication of the two RCT trials, the AOCG Practice Bulletin and the RANZCOG statement, we have not seen a surge in referrals. The actual referral pathway was not part of this clinical audit. It would be interesting to conduct a survey of GPs and gynaecologists, regarding the level of knowledge and attitudes towards this now well-established treatment option.

We acknowledge that this is a small single-operator two-centre audit on a selective population that is predominantly Caucasian in a locality of high socioeconomic status. UAE provides for quicker return to normal activity and less morbidity than hysterectomy and should therefore represent a viable and attractive option in other socioeconomic groups as well. With an increasing diversity of the Australian population, a national registry would be desirable to monitor the efficacy of this treatment on different racial and socioeconomic subgroups.

## Conclusions

This clinical audit, based on local Australian experience, has confirmed what has been widely reported in the international literature, that UAE is a safe and highly effective treatment for women with symptomatic fibroids and/or adenomyosis. Our results demonstrate that our clinical success rate in treating symptoms of menorrhagia, dysmenorrhoea and urinary symptoms is higher than that reported in multicentre trials and previous series. This is probably due to our multidisciplinary approach in woman selection and concentrated operator experience using a consistent protocol. There was quite a high incidence of adenomyosis presenting with fibroid-like symptoms. We have found that UAE is as effective in treating adenomyosis as fibroid disease. The procedure was safe, and there were no significant procedural-related complications.

## Acknowledgements

The authors express their gratitude to Kerry Bell for her assistance in data collection and manuscript preparation. We also thank Brian Banuag for his help in data collection and analysis.

## References

- 1 Wong YH, Liang EY, Ng TK, Lau KY. A cervical ectopic pregnancy managed by medical treatment and angiographic embolization. *Aust N Z J Obstet Gynaecol* 1999; **39** (4): 493–496.
- 2 Ravina JH, Herbretreau D, Ciraru-Vigneron N *et al.* Arterial embolisation to treat uterine myomata. *Lancet* 1995; **346** (8976): 671–672.
- 3 Medical Services Advisory Committee. Uterine artery embolization for the treatment of symptomatic uterine fibroids, Assessment Report January 2006. [Accessed 26 January 2011.] Available from URL: <http://www.msac.gov.au/>.
- 4 The Royal Australian and New Zealand College of Obstetricians and Gynaecologists. Uterine Artery Embolisation for the treatment of Uterine Fibroids. College Statement C-Gyn 23 1st Endorsed: March 2008. [accessed on 26 January 2011.] Available from URL: <http://www.ranzcog.edu.au/publications>.
- 5 Volkers NA, Hehenkamp WJ, Birnie E *et al.* Uterine artery embolization versus hysterectomy in the treatment of symptomatic uterine fibroids: 2 years outcome from the randomized EMMY trial. *Am J Obstet Gynecol* 2007; **196** (6): 519.e1–519.e11.
- 6 Edwards RD, Moss JG, Lumsden MA *et al.* Uterine-artery embolization versus surgery for symptomatic uterine fibroids. *N Engl J Med* 2007; **356** (4): 360–370.
- 7 ACOG Practice Bulletin. Alternatives to hysterectomy in the management of leiomyomas. *Obstet Gynecol* 2008; **112** (2 Pt 1): 387–400.
- 8 Hickey M, Hammond I. What is the place of uterine artery embolisation in the management of symptomatic uterine fibroids? *Aust N Z J Obstet Gynaecol* 2008; **48** (4): 360–368.
- 9 National Health and Medical Research Council, Australian Government. When does Quality Assurance in Health Care Require Independent Ethical Review? [Accessed 6 January 2011.] Available from URL: <http://www.nhmrc.gov.au/publications/synopses/e46syn.htm>.
- 10 Liang EY. Uterine fibroid embolization: a non-surgical alternative. [accessed on 26 January 2011.] Available from URL: <http://www.sir.net.au/UFEmain.html>.
- 11 Liang EY. Uterine fibroid embolization woman information. [accessed 26 January 2011.] Available from URL: <http://www.sir.net.au/UFEmaininfo.html>.
- 12 Waltman AC, Courey WR, Athanasoulis C, Baum S. Technique for left gastric artery catheterization. *Radiology* 1973; **109**: 732–734.
- 13 Spies JB, Cooper JM, Worthington-Kirsch R *et al.* Outcome of uterine embolization and hysterectomy for leiomyomas: results of a multicenter study. *Am J Obstet Gynecol* 2004; **191** (1): 22–31.
- 14 Spies JB, Allison S, Flick P *et al.* Polyvinyl alcohol particles and tris-acryl gelatin microspheres for uterine artery embolization for leiomyomas: results of a randomized comparative study. *J Vasc Interv Radiol* 2004; **15** (8): 793–800.
- 15 Lyon SM, Cavanagh K. RACGP | Uterine artery embolisation – a treatment alternative for women with fibroids. [Accessed 6 January 2011.] Available from URL: <http://www.racgp.org.au/afp/200605/5829>.
- 16 Spies JB, Coyne K, Guaou NG *et al.* The UFS QOL, a new disease specific symptom and health related quality of life questionnaire for leiomyomata. *Obstet Gynecol* 2002; **99** (2): 290–300.
- 17 Kim MD, Kim S, Kim NK *et al.* Long-term results of uterine artery embolization for symptomatic adenomyosis. *Am J Roentgenol* 2007; **188** (1): 176–181.